

## Recall Phenomenon After Intracranial Stereotactic Radiotherapy: Illustration of a Palpebral Reaction

Katsumasa Nakamura<sup>1\*</sup>, Tetsuo Nishimura<sup>2</sup> and Kazuhiko Ogawa<sup>3</sup>

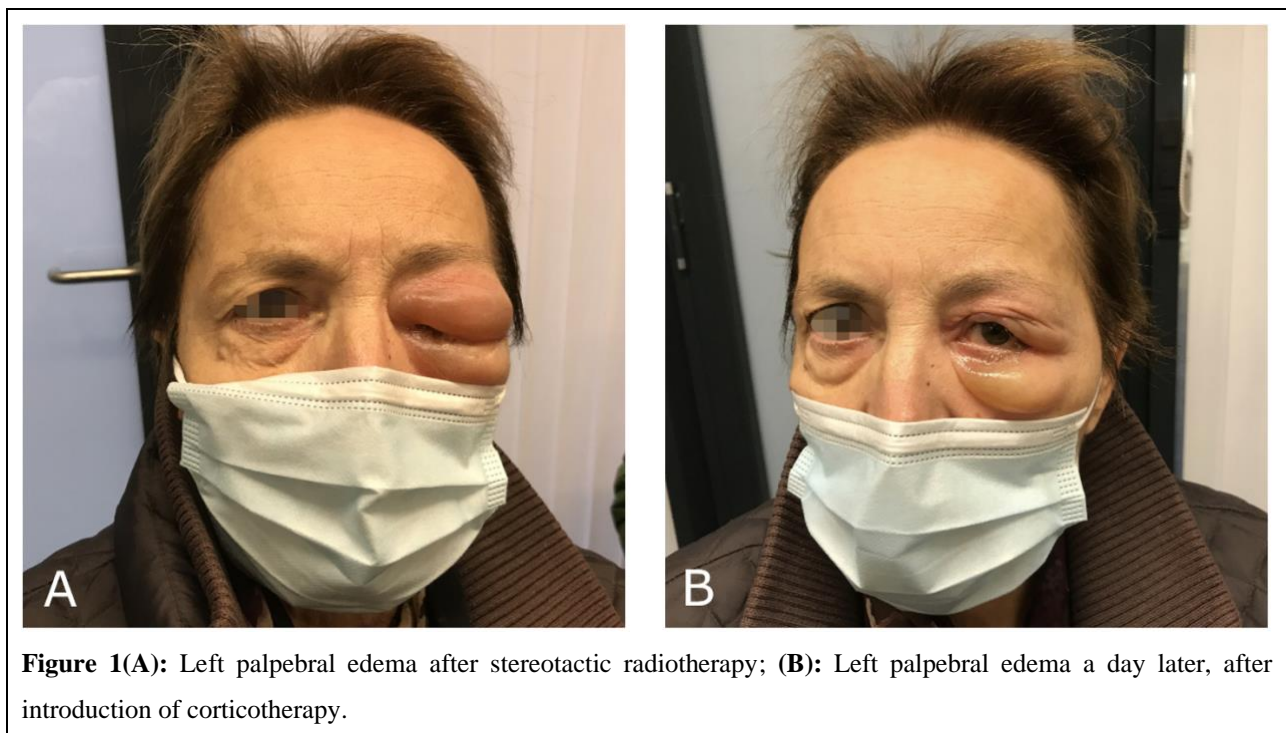<sup>1</sup>Department of Radiation Oncology, Hamamatsu University Hospital, 1-20-1 Handayama, Higashi-ku, Hamamatsu-shi, Shizuoka, 431-3192, Japan

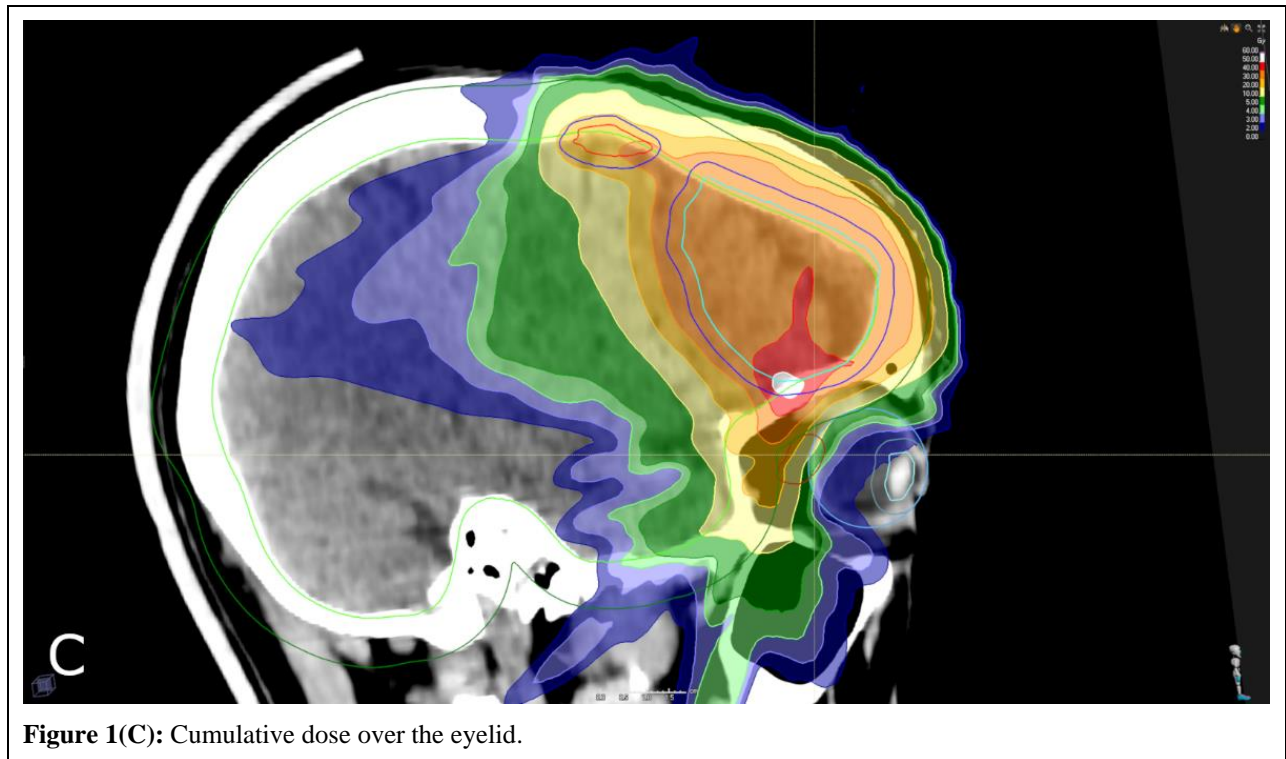
<sup>2</sup>Division of Radiation Oncology, Shizuoka Cancer Center Hospital, 1007 Shimonagakubo, Nagaizumi-cho, Sunto-gun, Shizuoka, 411-8777, Japan

<sup>3</sup>Department of Radiation Oncology, Osaka University Graduate School of Medicine, 2-2 Yamadaoka, Suita-shi, Osaka, 565-0871, Japan

\*Corresponding author: Katsumasa Nakamura, Department of Radiation Oncology, Hamamatsu University Hospital, 1-20-1 Handayama, Higashi-ku, Hamamatsu-shi, Shizuoka, 431-3192, Japan. E-mail: [nakakatsuhm19@gmail.com](mailto:nakakatsuhm19@gmail.com)

**Received:** November 13, 2021; **Accepted:** November 22, 2021; **Published:** December 05, 2021





### Clinical Image

A 57-year-old woman, known for metastatic breast cancer, presented in November 2020 with a newly left intraorbital metastasis on MRI. The patient had a history of radiotherapy for focal leptomeningeal metastasis surrounding the area (left temporal), receiving 20 Gy in one fraction 7 months before. We irradiated this new metastasis delivering a fractionated stereotactic radiotherapy of 35 Gy in 7 fractions with a Cyberknife® system. The patient started a metronomic chemotherapy schema of Cyclophosphamide (50 mg daily) and Methotrexate (2.5 mg 2x/day) one week before the first day of radiotherapy. The day after the first fraction, she presented a severe left-eye palpebral edema (Figure 1A).

Other causes of eyelid edema were excluded by our ophthalmologist. We prescribed oral Dexamethasone 8 mg the first day, followed by a tapering schedule, associated with eye antibiotic eye drops and vitamin A ointment for 7 days. The edema rapidly decreased 24 hours after the corticotherapy was started (Figure 1B). The patient could resume the radiotherapy after a single day interruption.

We depict a recall phenomenon at an unusual location after radiotherapy in a patient sensitized by a history of radiotherapy and chemotherapy. Two chemotherapeutic agents were given, with compatible timing and reactions as described in literature. The reported delay is 5 to 7 days for Methotrexate and few hours for Cyclophosphamide; both drugs can induce cutaneous reactions. We believe that combining these chemotherapeutic agents with the delivery of radiotherapy in a previously irradiated area triggered an inflammatory response that induced a recall phenomenon. The cumulative Dmean over the left eyelid was 7.6 Gy (Figure 1C).

Radiation recall is defined as an inflammatory response within a previously irradiated region after chemotherapy. A theory claims that cytotoxic treatment following radiation generates a 'remembered' reaction in the remaining surviving cells inside the previously treated zone.

### **Contributors**

We all took care of the patient, wrote the report, and interpreted the data. Written consent for publication was obtained from the patient. The patient mentioned preferring the picture to have the healthy eye pixelated.

**Keywords:** Stereotactic radiation; CyberKnife; Recall phenomenon; Eyelid edema