

Colonic Stricture in Ulcerative Colitis: Diagnosis Out-of-the-Way

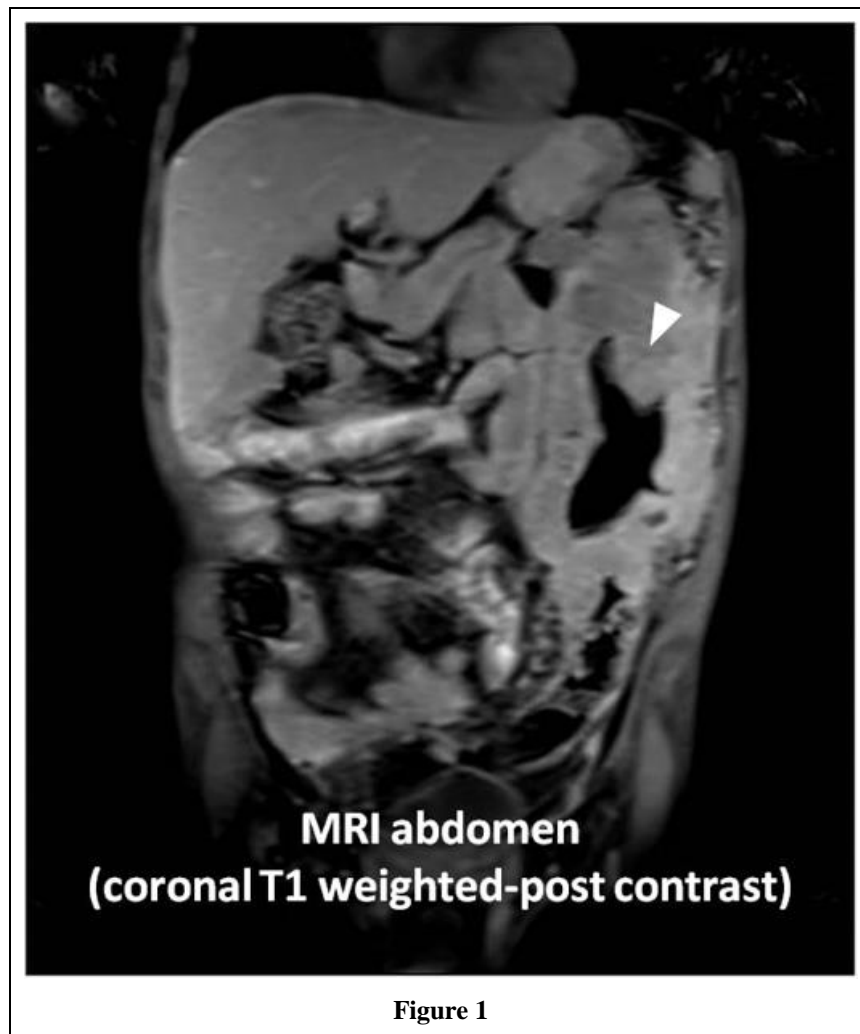
Rohit Mathur^{1*}, Arathi S Gadwalkar¹, Arun Karyampudi¹, Anuradha Sekaran² and D Nageshwar Reddy¹

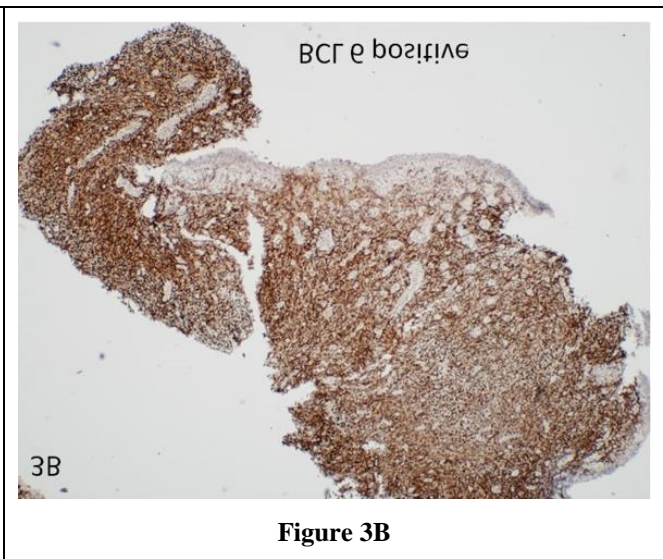
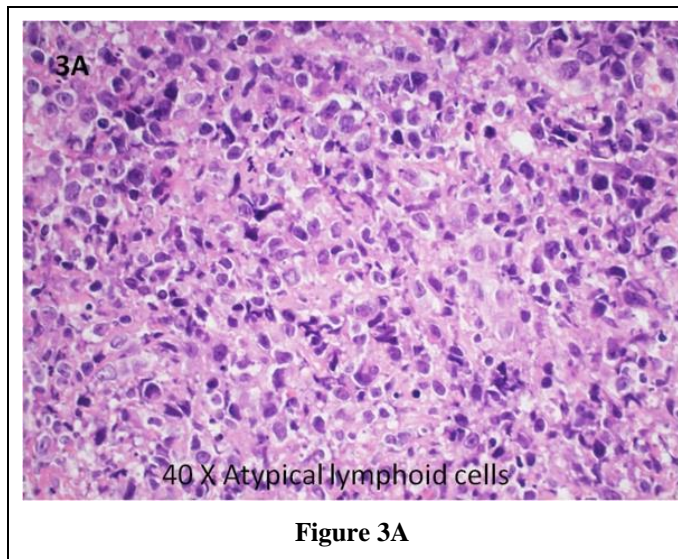
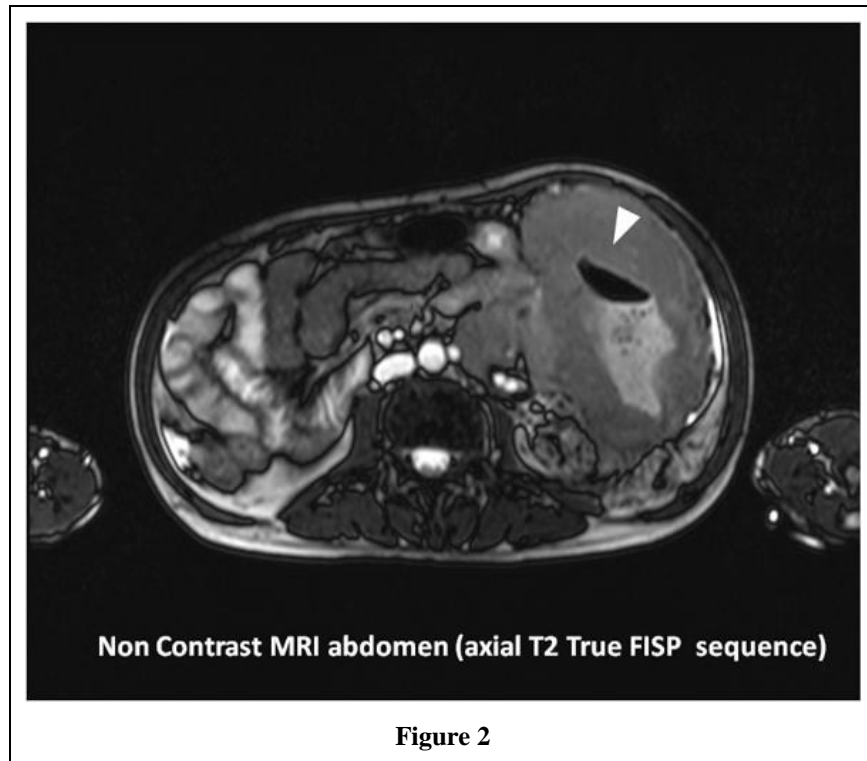
¹Department of Gastroenterology, Asian institute of gastroenterology, Hyderabad, India

²Department of Pathology, Asian institute of gastroenterology, Hyderabad, India

*Corresponding author: Dr Rohit Mathur, Department of Gastroenterology, Asian institute of gastroenterology, Somajiguda, Telangana, Hyderabad, India. E-mail: rohitmathur2021@gmail.com

Received: October 12, 2022; Accepted: October 23, 2022; Published: November 05, 2022





Abstract

A 51-year Asian man, with ulcerative colitis (UC) for 10 years, presented as 8 months history of intermittent abdominal pain and change in bowel habits, feeling of lump-in-abdomen, tenesmus, bleeding per rectum and significant weight loss for 2 months. He was never on immunosuppressant for UC. MRI abdomen showed circumferential enhancing thickening (up to 6.8cm) of the left colon (Figures 1 and 2) extending from splenic flexure distally for a length of 24 cm. Colonoscopy showed loss of normal vascular pattern, mucosal friability and nodularity with luminal narrowing in the descending colon. Biopsy showed clusters of atypical lymphoid cells with expression of lymphoid surface antigens (CD45, CD20 and CD3) negative for cytokeratin (Figure 3A). Additionally, tumour cells showed Bcl-2, Bcl-6, and focal c-MYC positivity (Figure 3B) with Ki67 proliferative index of 50% and no MUM1 expression, suggestive of non-Hodgkin diffuse large B-cell lymphoma of germinal origin. Primary colorectal lymphoma (PCL) [1] occurs more commonly in patients of inflammatory bowel disease who are on long term immunosuppressant and carries a poorer prognosis than NHL of other gastrointestinal sites. Its occurrence de novo in an untreated patient of ulcerative colitis is extremely rare. Histologically, non-Hodgkin's lymphoma (NHL) is more common than Hodgkin's lymphoma. The exact aetiology is not known, although infection with Epstein-Barr virus may play a role [2]. This patient the Dawson criteria [3] for PCL and was started on chemotherapy after WHO staging fulfilled. Better imaging and advances in IHC techniques made this diagnosis possible.

Work involved in manuscript

Dr Rohit Mathur - Study concept and design, acquisition of data, drafting of the manuscript, analysis and interpretation of data.

Dr Arun Karyampudi - Study supervision, interpretation of data, material support.

Dr Anuradha Sekaran - Study supervision, acquisition of data, interpretation of data.

Dr Arathi. S. Gadwalkar - Acquisition of data.

Dr D N Reddy - Chief gastroenterologist Asian institute of gastroenterologist - Study supervision.

REFERENCES

1. Dionigi, G. Primary Colorectal Lymphomas: Review of the Literature. *Surgical Oncology*. 2007; 16: 169-171.
2. Bernardes Carlos. Lymphoproliferative Disorders in Inflammatory Bowel Disease Patients: Is it the Drugs or the Disease. *GE-Portuguese Journal of Gastroenterology*. 2018; 175-178.
3. Dawson IMP, J S Cornes, BC Morson. Primary Malignant Lymphoid Tumours of the Intestinal Tract. Report of 37 Cases with a Study of Factors Influencing Prognosis. *British Journal of Surgery*. 1961; 80-89.