

## When is a Stye not a Stye?

**Kyle R. Fischer<sup>1</sup>, Adam C. Richardson<sup>2\*</sup>, Kelly M. Blosser<sup>2</sup> and Jason D. Adler<sup>1</sup>**

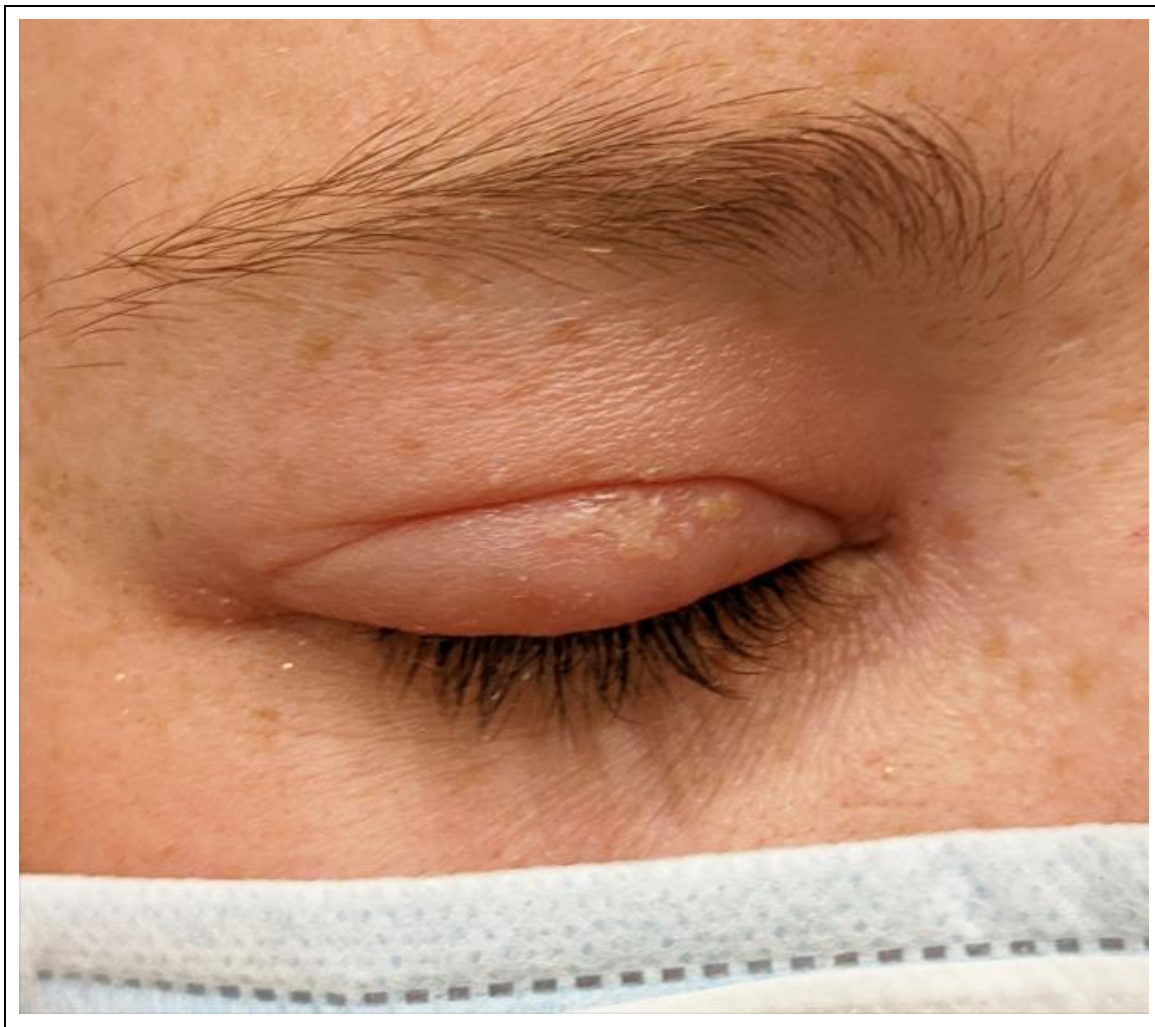<sup>1</sup>University of Maryland School of Medicine, Department of Emergency Medicine, Baltimore, Maryland

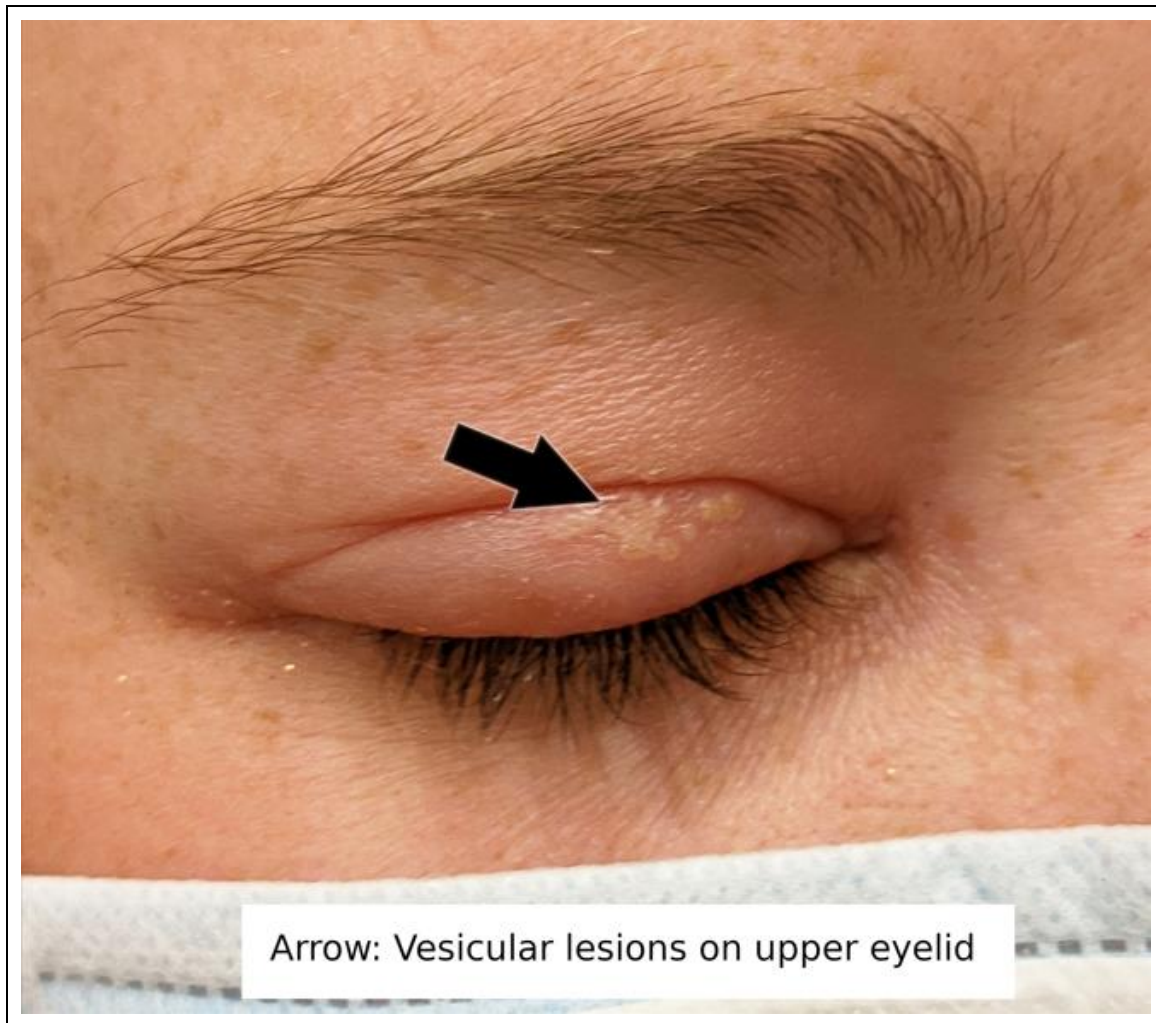
<sup>2</sup>University of Maryland Medical Center, Department of Emergency Medicine, Baltimore, Maryland

\***Corresponding author:** Adam C. Richardson, DNP, ENP-C, Department of Emergency Medicine, University of Maryland.

E-mail: [adamrichardson@umm.edu](mailto:adamrichardson@umm.edu)

**Received:** September 07, 2022; **Accepted:** September 15, 2022; **Published:** October 02, 2022





### **Clinical Image**

A 25 year old female with no significant medical history presented to the emergency department with a one day history of mildly painful and erythematous swelling of her right upper eyelid that she believed to be either a stye or conjunctivitis. She was triaged to the ED's fast track. She denied vision changes, other skin lesions or sick contacts. The clinical team noted vesicular lesions located exclusively on the upper eyelid and initiated valacyclovir [1].

She promptly followed-up with ophthalmology who confirmed the diagnosis of Varicella zoster virus. There was no evidence of corneal involvement and her dilated exam was reassuring. Erythromycin ointment was added to prevent a superimposed bacterial infection and antivirals were continued for ten days.

Given the location of the lesions on the lid, only fully visible with complete closure of the eye, a careful examination was critical in making an accurate diagnosis. Particularly when patients believe a diagnosis to be known and benign, it is important for physicians to avoid anchoring bias, as it can be easy to overlook lesions like these. It is important to not miss zoster this close to the eye [2].

## REFERENCES

1. Yeu E, Hauswirth S. A Review of the Differential Diagnosis of Acute Infectious Conjunctivitis: Implications for Treatment and Management. *Clinical Ophthalmology*. 2020; 14: 805.
2. Carlisle RT, Digiovanni J. Differential Diagnosis of the Swollen Red Eyelid. *American Family Physician*. 2015; 92: 106-112.