

## Co-administration of mTor Inhibitors and Carbamazepine May Lead to Ineffectiveness of Therapy: A Case Report of a 24-year-old Man

Asma Sawan<sup>1\*</sup>, Guillaume Becker<sup>2</sup>, Paul Lefevre<sup>2</sup>, Daniel Brumar<sup>2</sup>, Jean Pierre Bergerat<sup>3</sup>, Jean Marc Lessinger<sup>2</sup> and Véronique Kemmel<sup>2</sup>

<sup>1</sup>Department of Microbiology and Medical Parasitology, King Abdulaziz university Hospital, King Abdulaziz University, Jeddah, Kingdom of Saudi Arabia

<sup>2</sup>Biochemistry and Molecular Biology Department, University Hospital of Strasbourg, Avenue Molière, Strasbourg, France

<sup>3</sup>Oncology and Hematology Department, Hôpital de Hautepierre, University Hospital of Strasbourg, avenue Molière, Strasbourg, France

\*Corresponding author: Asma Sawan, Department of Microbiology and Medical Parasitology, King Abdulaziz university Hospital, King Abdulaziz University, Jeddah, Kingdom of Saudi Arabia. E-mail: [Asma.a.sawan@gmail.com](mailto:Asma.a.sawan@gmail.com)

**Received:** February 15, 2022; **Accepted:** February 23, 2022; **Published:** March 10, 2022

### Abstract

**Adverse Event:** Drug interaction leading to low exposure of mTor inhibitors and their ineffectiveness.

**The Patient:** A 24-year-old male patient, known to have tuberous sclerosis complex since birth, developed renal epithelioid angiomyolipomas with hepatic metastasis. Everolimus treatment failed after 8 months of administration, this led to a switch to temsirolimus treatment without more efficiency that appeared later on was due to drug-drug interaction which was dealt with in an effective manner.

**Evidence that Links the Drug to the Event:** The timeline was consistent with the administration of carbamazepine for epilepsy attacks. A pharmacokinetic analysis showed a decrease in sirolimus and temsirolimus blood concentrations.

**Management:** Therapeutic drug monitoring of temsirolimus and sirolimus led us to conclude that a threefold increase in the dose of temsirolimus was needed to ensure the effectiveness of treatment without adverse effects.

**Conclusion:** Clinicians should be aware of the potential drug interactions with mTor inhibitors in individuals using antiepileptic drugs. Close monitoring is necessary by measuring temsirolimus and/or sirolimus and/or everolimus concentrations in the blood.

**Keywords:** mTor inhibitors; Temsirolimus; Sirolimus

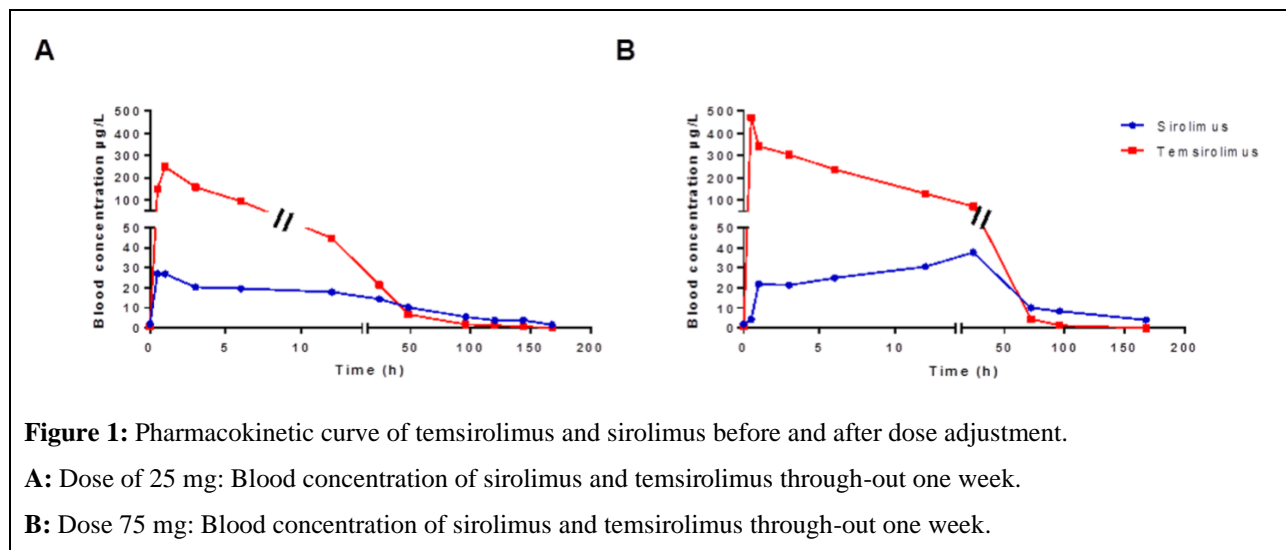
## Introduction

Temsirolimus, sirolimus and everolimus are inhibitors of the mammalian target rapamycin (mTOR), an enzyme that regulates cell growth and proliferation. Temsirolimus is a prodrug of sirolimus. Although mTOR inhibitors are known to be extensively metabolized by cytochrome P450 3A4 (CYP3A4), no drug monitoring is systematically recommended when these molecules are administered for cancer therapy in contrast to what is recommended for organ transplantations [1]. We report on a probable interaction between mTor inhibitors and carbamazepine (an enzyme-inducing antiepileptic drug), in which carbamazepine leads to an ineffectiveness of everolimus and temsirolimus therapy which is resolved by a dose adjustment after drug monitoring.

## Case Report

Here we describe a case of a 24-year-old male patient who had been known to have tuberous sclerosis complex (TSC) since birth. At the age of 6, the patient developed a cerebral tumor which was resected successfully, and had been maintained on oral levetiracetam 500 mg three times daily and topiramate 100 mg twice daily for several years. At the age of 20, he was discovered to have malignant multiple bilateral renal epithelioid angiomyolipomas (EAML), for which the patient underwent right nephrectomy, selective radiological embolization and cryotherapy for three EAML of the left kidney. A year later, he was discovered to have a retro-caecal retroperitoneal mass and a right adrenal mass in which the patient underwent a surgical intervention for a complete removal of this retroperitoneal mass and a right adrenalectomy, histopathological analysis revealed malignant renal EAML. At the age of 22, the patient underwent an imaging follow-up computer tomography (CT) scan which showed a retroperitoneal mass (inter aortic-cave) and hepatic lesions; with a liver puncture biopsy result showing EAML metastasis. Treatment was initiated by everolimus for 8 months, during those 8 months, we noticed stability of the hepatic metastasis and the renal EAML. Unfortunately, this line of treatment failed with augmentation of liver metastasis afterwards. Everolimus trough whole blood concentrations determined by LC/MS<sup>2</sup> technique were low but stable, between 1.5 and 4.0 µg.L<sup>-1</sup>. This led us to switch to temsirolimus, with a weekly dose administration of 25 mg. This switch did not show any sign of clinical nor radiological improvement on the patient what so ever leading us to believe that there might be a possible drug interaction in the equation. Our patient had been taking carbamazepine 400 mg twice a day for his epilepsy attacks. Carbamazepine is an antiepileptic drug which is metabolized primarily in the liver by CYP3A4 and is an inducer of CYP3A4 enzyme, which increases the clearance of many drugs including everolimus and sirolimus and decreases their concentration in the blood to sub-therapeutic levels leading to a reduction in their desired effect. Monitoring of carbamazepine plasma concentration showed carbamazepine values between 10.4 and 14.9 mg. L<sup>-1</sup> (reference values 4-12 mg.L<sup>-1</sup>). A therapeutic drug monitoring, was proposed by measuring temsirolimus and sirolimus concentrations in the blood by LC/MS<sup>2</sup> techniques. The area under the concentration curve (AUC) for both molecules was measured. We noticed that with a dose of 25 mg of temsirolimus, the AUC reached 2.35 h. µg. mL<sup>-1</sup>, whereas the AUC described in the literature for temsirolimus was between 2.70 ± 0.72 [2] and 5.03 ± 2.92 h.µg.mL<sup>-1</sup> [3] however no effective therapeutic target is defined. While for sirolimus, the AUC was 1.37 h.µg.mL<sup>-1</sup>, however the AUC described in the literature for sirolimus was between 13.30 ± 3.70 [2] and 14.49 ± 4.94 h.µg.mL<sup>-1</sup> [3] for patients not on enzyme-inducing epileptic drugs (EIAED), whereas patients receiving EIAED showed a 1.5-fold lower systemic exposure to temsirolimus and a 2-fold lower exposure to sirolimus [2,3].

And on top of that, sirolimus concentrations in the blood disappeared between the 2nd (6.8  $\mu\text{g. L}^{-1}$ ) and 3rd day (1.7  $\mu\text{g. L}^{-1}$ ) after introduction of carbamazepine, explaining the ineffectiveness on the hepatic metastasis. As a consequence, we increased the doses of temsirolimus and sirolimus until reaching an AUC of 6.06  $\text{h.}\mu\text{g.mL}^{-1}$  and 2.51  $\text{h.}\mu\text{g.mL}^{-1}$  for temsirolimus and sirolimus respectively. Temsirolimus reached an effective therapeutic zone of 75 mg weekly and was still detected in the blood at the 7th day postadministration (T168 Hour, 4.1  $\mu\text{g. L}^{-1}$ ). Blood concentrations of sirolimus and temsirolimus at doses of 25 mg and 75 mg through-out the week are shown in Figure 1. At these specific concentrations, we started noticing regression of the hepatic metastasis and renal EAML with improvement of the general state of the patient. Unfortunately, the patient relapsed one year later and developed an insulinoma going into palliative treatment and passed away soon after.



**Figure 1:** Pharmacokinetic curve of temsirolimus and sirolimus before and after dose adjustment.

**A:** Dose of 25 mg: Blood concentration of sirolimus and temsirolimus through-out one week.

**B:** Dose 75 mg: Blood concentration of sirolimus and temsirolimus through-out one week.

## Discussion

EAML was first described by Mai et al in 1996 [4]. It is a rare mesenchymal tumor which has been gradually recognized and accepted as a distinct entity in recent years. Renal EAML is a rare renal neoplasm accounting for less than 1% of renal epithelial neoplasms, with a male to female ratio of 1:3 [5]. The current World Health Organization Classification of Renal Neoplasms classifies renal EAML as “a potentially malignant mesenchymal neoplasm” with adverse outcomes in approximately one-third of cases. TSC is an autosomal dominant multi- system disease that can manifest with seizures, mental retardation, autism, and tumors in the brain, retina, kidneys and heart, and is caused by germline mutations in either TSC1 or TSC2 genes located on chromosomes 9 and 16, respectively. With renal involvement being the main cause of mortality and morbidity in patients older than 30 years [6,7]. The TSC1 and TSC2 genes encode proteins that form the hamartin and tuberlin tumor suppressor complex, which restricts the activation of mammalian target of rapamycin complex 1 (mTORC1) [7]. Everolimus is a rapamycin derivative that inhibits the mTOR pathway by acting on mTORC1 [8]. In AML, the first study demonstrating the effect of mTOR inhibitors was in 2008, in which patients were treated with sirolimus over a 12-month period [9]. All patients showed a reduction in AML size. This first study was followed by a large, multicenter, prospective randomized trial (EXIST-2) evaluating the effect of everolimus on AML. With 118 adult patients, of whom 79 were treated with everolimus 10 mg/day and 39 received placebo.

After 24 weeks, 55% of patients in the treatment group showed a >50% reduction in AML volume compared with 0% in the control group [10]. Results of the EXIST-2 trial led to the approval of everolimus for TSC associated AML worldwide. Thus, everolimus therapy is the primary recommended treatment, allowing patients to avoid surgical procedures and preserving their kidneys [11,12].

In our case, everolimus showed simply stability of the hepatic metastasis and renal EAML size. Even if the trough blood concentrations of everolimus were low no recommendation exist to adjuste the dosage on blood concentrations. However, we switched to temsirolimus 8 months later after failure of everolimus. Yet, even this switch did show any sign of clinical nor radiological improvement on the patient. Since many of TSC patients suffer from seizures, they are kept on antiepileptic drugs and sometimes on carbamazepine. Which was the case in our patient. Carbamazepine is an inducer of CYP3A4, which increase clearance of everolimus and sirolimus, thus decreasing their effect. Temsirolimus is converted to the major metabolite sirolimus by deesterification (a non-cytochrome process). As we increased the dose of temsirolimus to the therapeutic zone, we started to see positive results. In subgroup analysis of EXIST-2 study, TSC AML patients under anti-epileptic medication presented with everolimus trough levels of 3.8 ng/ml, compared with 8.2 ng/ml for patients without anti- epileptic medication. This shows, like in our case, the undesired drug interaction between mTOR inhibitors and anti-epileptic medications. But no effect was observed on the efficacy of Everolimus [10]. Furthermore, drug interactions are real and can alter the whole management plan for certain patients. Thus, as in our case, awareness is necessary when using mTOR inhibitors with CYP450 3A4 enzyme inducing drugs.

## Conclusion

Metastatic renal EAML is a rare disease. With mTOR inhibitor treatment showing rather positive effect in an adequate therapeutic dose. Vigilance and awareness of drug interactions is of an extreme importance. These interactions can be overcome with proper drug or dose changes.

## REFERENCES

1. Widmer N, Bardin C, Chatelut E, et al. Review of therapeutic drug monitoring of anticancer drugs part two-targeted therapies. *European J Canc.* 2014; 50: 2020-2036.
2. Atkins MB, Hidalgo M, Stadler WM, et al. Randomized phase II study of multiple dose levels of CCI-779, a novel mammalian target of rapamycin kinase inhibitor, in patients with advanced refractory renal cell carcinoma. *J Clin Oncol.* 2004; 22: 909-918.
3. Kuhn JG, Chang SM, Wen PY, et al. Pharmacokinetic and tumor distribution characteristics of temsirolimus in patients with recurrent malignant glioma. *Clin Cancer Res.* 2007; 13: 7401-7406.
4. Mai KT, Perkins DG, Collins JP. Epithelioid cell variant of renal angiomyolipoma. *Histopathology.* 1996; 28: 277-280.
5. Faraji H, Nguyen BN, Mai KT. Renal epithelioid angiomyolipoma: A study of six cases and a meta-analytic study: Development of criteria for screening the entity with prognostic significance. *Histopathology.* 2009; 55: 525-534.
6. Astrinidis A, Henske EP. Tuberous sclerosis complex: linking growth and energy signaling pathways with human disease. *Oncogene.* 2005; 24: 7475-7481.
7. Avgeris S, Fostira F, Vagena A, et al. Mutational analysis of TSC1 and TSC2 genes in Tuberous Sclerosis Complex patients from Greece. *Sci Rep.* 2017; 7: 16697.

8. Tabernero J, Rojo F, Calvo E, et al. Dose- and schedule- dependent inhibition of the mammalian target of rapamycin pathway with everolimus: a phase I tumor pharmacodynamic study in patients with advanced solid tumors. *J Clin Oncol.* 2008; 26: 1603-1610.
9. Bissler JJ, McCormack FX, Young LR, et al. Sirolimus for angiomyolipoma in tuberous sclerosis complex or lymphangiomyomatosis. *N Engl J Med.* 2008; 358: 140-151.
10. Bissler JJ, Kingswood JC, Radzikowska E, et al. Everolimus for angiomyolipoma associated with tuberous sclerosis complex or sporadic lymphangiomyomatosis (EXIST-2): a multicentre, randomised, double-blind, placebo-controlled trial. *Lancet.* 2013; 381:
11. Krueger DA, Northrup H. Tuberous sclerosis complex surveillance and management: recommendations of the 2012 International Tuberous Sclerosis Complex Consensus Conference. *Pediatr Neurol.* 2013; 49: 255-265.
12. Pirson Y. Tuberous sclerosis complex-associated kidney angiomyolipoma: from contemplation to action. *Nephrol Dial Transplant.* 2013; 28: 1680-1685.