

Central Venous Catheter in Left Internal Mammary Artery

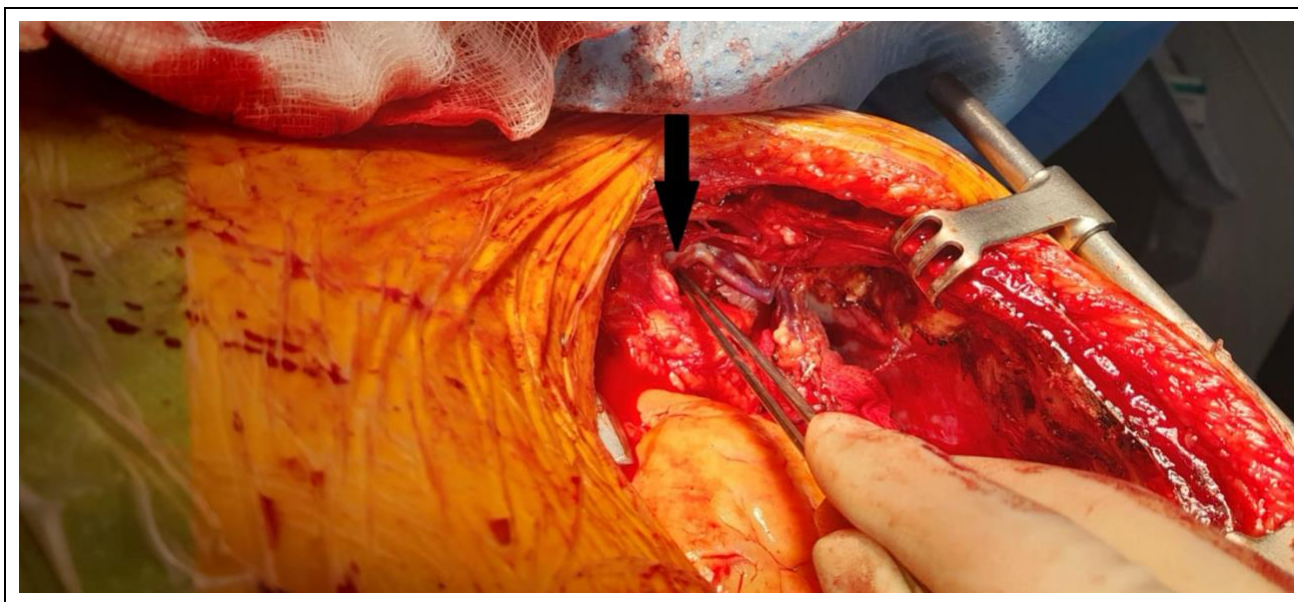
Bothayna Amien¹, Amer Harky^{1*}, Piotr Wolski² and Gopal Soppa¹

¹Department of Cardiothoracic Surgery, Liverpool Heart and Chest Hospital, Liverpool, UK

²Department of Cardiothoracic Anaesthesia, Liverpool Heart and Chest Hospital, Liverpool, UK

*Corresponding author: Amer Harky, Department of Cardiothoracic Surgery, Liverpool heart and chest hospital, Liverpool, UK. E-mail: amer.harky@lhch.nhs.uk

Received: September 21, 2023; Accepted: October 07, 2023; Published: October 25, 2023



Clinical Image

A left central venous catheter (CVC) was noted to be inside the left internal mammary vein (arrow). The CVC was inserted under ultrasound guide, no issues with medication administration. During sternotomy haemostasis, it was noted that clear fluids were coming out of sternal edges. Line repositioned afterward into femoral region.