Clinical Images and Case Reports Journal

Case Series | Vol 4 Iss 9

Laparoscopic Management of Acute and Chronic Tubo-ovarian Abscess in a Rural Setup: A Case Series

Sivakumar Thangappan[1], Dolly Johnrose[2] and Sharmila Sakthykumari Vandhana[3*]

[1]Head of the Department, Minimal Access Surgery, Siva Hospitals Institute of Minimal Access Surgery, Ethamozhy, Tamilnadu, India

[2]Consultant, Department of Obstetrics and Gynecology, Siva Hospitals Institute of Minimal Access Surgery, Ethamozhy, Tamilnadu, India

[3]Fellow in Endogynecology, Siva Hospitals Institute of Minimal Access Surgery, Ethamozhy, Tamilnadu, India

[*]**Corresponding author:** Sharmila Sakthykumari Vandhana, Fellow in Endogynecology, Siva Hospitals Institute of Minimal Access Surgery, West coast road, Ethamozhy, Tamilnadu, India. E-mail: ssvandhana@gmail.com

Received: August 04, 2022; **Accepted:** August 16, 2022; **Published:** September 02, 2022

Abstract

Introduction: Tubo-ovarian abscess represents a severe form of pelvic inflammatory disease with high morbidity. Management of tubo-ovarian abscesses is complex and depends on various factors like size of the abscess, condition of the patient and response to antibiotics. Surgical management is not commonly preferred and is reserved for large abscesses and failed medical management.

Case Series: We present a case series of surgically managed patients with tubo-ovarian abscesses. The first case demonstrates a patient who underwent emergency laparoscopy after a long antibiotic course for a misdiagnosed dermoid cyst which turned out to be a chronic tubo-ovarian abscess and had a difficult and long operative procedure due to dense intrapelvic adhesions. Our second patient presented with acute abdomen, sepsis and rapidly deteriorating clinical condition, underwent early laparoscopic intervention within 24hrs suspecting tubo-ovarian abscess rupture and had a rapid recovery after a short operative procedure. The third case demonstrates a chronic tubo-ovarian abscess with dense intrapelvic adhesions in a patient with primary infertility who underwent a difficult laparoscopic surgical intervention for the endometriotic cyst.

Conclusion: Early laparoscopic surgical intervention in abscesses more than 5cm gives a favorable outcome to the patient irrespective of the initial response to antibiotics. Timely laparoscopic intervention in patients is beneficial to avoid prolonged hospitalization, antibiotic usage, and faster recovery. Diagnosis of a tubo-ovarian abscess requires a high degree of suspicion as delay in the diagnosis was the major reason for late surgical intervention.

Copyright: *All articles published in the Clinical Images and Case Reports Journal are the property of Literature Publishers, and is protected by copyright laws. Copyright © 2022, Literature Publishers, All Rights Reserved.*

Keywords: Tubo-ovarian abscess; Failed medical management; Laparoscopy; Surgical intervention

Introduction

Tubo-Ovarian Abscess is a potentially life-threatening complication of untreated Pelvic Inflammatory Disease and occurs in 15-35% of females treated for proven Pelvic Inflammatory Disease [1]. Tubo-ovarian abscess is defined as an inflammatory mass involving the tube or ovary characterized by the presence of pus. The most common cause is ascending genital tract infection causing the initial pelvic inflammatory disease which progresses to tubo-ovarian abscess [2]. Bacteroides, E. coli and Peptococcus are some of the most prevalent pathogenic bacteria found in tubo-ovarian abscess [3]. Classically, a tubo-ovarian abscess manifests with an adnexal mass, fever, elevated white blood cell count, lower abdominal-pelvic pain, vaginal discharge; however, presentations of this disease can be highly variable [4]. Treatment of pelvic inflammatory disease complicated with tubo-ovarian abscess includes broad spectrum antibiotics and minimally invasive drainage procedures with or without surgery [5]. Medical management might not be adequate in tubo-ovarian abscesses due to poor antibiotic penetration in large masses [3]. Rapid clinical deterioration may need prompt surgical intervention in up to 25% [6]. In many instances tubo-ovarian abscess may be misdiagnosed and adequate treatment might not reach the patient at the appropriate time. Surgery may be conservative or require pelvic clearance depending on the clinical situation [1]. Potential long-term complications of tubo-ovarian abscess include infertility, chronic pelvic pain, distorted pelvic anatomy, recurrent pelvic inflammatory disease and increased risk of ectopic pregnancy [7].

We present a case series of three patients with acute and chronic tubo-ovarian abscesses who underwent surgical intervention.

Case Series

Case 1

A 45year old multiparous lady with a history of previous two caesarean sections, irregular menstrual cycles (5/90), living with spouse and not sterilized, presented with complaints of severe abdominal pain and low-grade fever for 3 days. She gave a history of abdominal pain, low-grade fever and loose stools for 10 days that was medically managed as urinary tract infection and renal stones with intravenous antibiotics at a local hospital. As the symptoms persisted, ultrasound of the abdomen and pelvis was done which showed right vesicoureteric junction calculus of size 4mm, hydrouretero nephrosis and cystitis with bilateral ovarian simple cysts of size 3.6 x 3.3cm in the right ovary and 3 x 4cm in left ovary. Despite medical management, her symptoms persisted. Hence plain CT abdomen and pelvis was done which showed a heterogeneous mass in the left ovary of size 5.8 x 6cm with fat stranding and calcification which was suggestive of ovarian teratoma (Figure 1). She was referred to our center for laparoscopic management of the ovarian cyst.

On admission, she was anemic, thin-built (BMI <18.5), malnourished with oral ulcers and angular stomatitis. She had a low-grade fever (Temperature 99° F), pulse rate of 90 per minute, respiratory rate of 18 per minute, and blood pressure of 100/50 mmHg. Her per abdominal examination showed tenderness in the right paraumbilical area extending into the right iliac fossa with a vague irregular mass palpable on the right side. Mild left iliac fossa tenderness was noted. Her basic investigations revealed haemoglobin of 7.9gms with elevated white blood cell count and C-reactive protein. Suspecting ovarian torsion she was taken up for emergency laparoscopy after basic investigations and preoperative intravenous antibiotics.

Her intraoperative findings revealed a tubo-ovarian abscess of size 6x6 cm involving both tubes and ovaries with dense intrapelvic adhesions and sheets of pus. The left ovary had a Dermoid cyst of size 4 x 4cm and a simple cyst of size 2 x 2cm. Patient underwent bilateral tubo-ovarian abscess drainage, adhesiolysis, bilateral salpingectomy, and omentectomy with peritoneal lavage. The left ovarian Dermoid cyst and simple cyst were removed and an intraabdominal drain was placed in the pouch of Douglas. The total duration of surgery was 240 minutes and about 120 minutes of it were spent on adhesiolysis. The specimen was sent for histopatholoy and pus was sent for culture and sensitivity. The histopathological report was consistent with left dermoid cyst with inflammation of the omentum and the Pus culture was sterile probably due to prolonged antibiotics for about 10 days before surgery.

Postoperatively, the patient was treated with broad-spectrum intravenous antibiotics and transfused with 3 units of the packed cell. Thromboprophylactic measures were also taken. The drain was removed on postoperative day 4. The patient improved symptomatically and was discharged on postoperative day 7. The patient was continued on oral antibiotics for 14 days along with iron and multivitamin supplements. She was followed up for 3 months and found to be asymptomatic with regular menstrual cycles.



Figure 1: Transverse section of Abdomen and pelvis in Computed Tomography plain of case 1 showing left ovarian Dermoid cyst of size 5.8 x 6 cm with fat stranding and calcification and right tubo-ovarian mass of size 4 x 3 cm.

Case 2

A 46-year-old multiparous lady with two previous caesarean sections, regular menstrual cycles, sterilized and living with her spouse, initially presented to the emergency room with worsening abdominal pain for 1 week and a high-grade fever for 3 days. At the time of admission, the patient had a temperature of 101°F, a pulse rate of 110per minute, tachypnea with a saturation of 99% in room air, and blood pressure of 90/50 mmHg. Laboratory evaluation revealed elevated white cell count (Neutrophilia 75%), CRP 25 and hemoglobin 8.6g/dl. She gave a history of chronic pelvic pain for 3 months for which she had been treated in various hospitals. Physical examination revealed warmth, guarding, and tenderness in the left iliac fossa. She was started on intravenous broad-spectrum antibiotics. CT abdomen and pelvis showed evidence of tubular cystic lesions in bilateral adnexa of size 6.2 x 1.9cm on the right and 6.4 x 2.5 cm on the left with perilesional hyperechoic edema, edematous small bowel loops, and moderate free fluid in the abdomen and pelvis (Figure 2-4).

She was taken up for emergency laparoscopy suspecting abscess rupture and because of her worsening general condition. Intraoperatively we noted bilateral pyosalphinx of size 6 x 4 cm in the right adnexa and 6 x 5cm in the left adnexa with liquid pus in the pelvic cavity. Intraabdominal and perihepatic adhesions was also seen (Fitz Hugh Curtis Syndrome). The patient underwent bilateral tubo-ovarian abscess drainage with bilateral salpingectomy with peritoneal lavage. Pus was sent for culture and sensitivity. An intra-abdominal drain was placed. The total duration of surgery was one hour.

Pus culture showed growth of Pseudomonas and *Escherichia coli*. Post operatively she was treated with broad-spectrum intravenous antibiotics and which was later changed based on the culture and sensitivity report of the drained pus. The drain was removed on postoperative day 5. Postoperative pelvic ultrasound showed no fluid collection in the abdominal cavity. The patient was symptomatically better and was discharged on the 7th post-operative day. She was continued on oral antibiotics for 28 days along with iron and multivitamin tablets. She was followed up for 3 months and she was found to be asymptomatic.

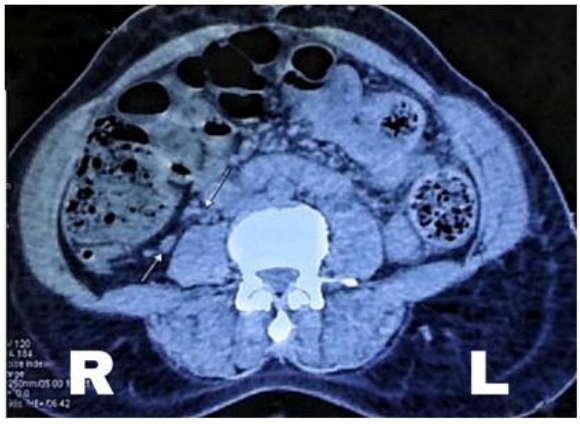

Figure 2: Transverse section of Abdomen and pelvis in Contrast Enhanced Computed Tomography of case 2 showing tubular cystic lesion in right adnexa of size 6.2 x 1.9 cm.



Figure 3: Transverse section of Abdomen and pelvis in Contrast Enhanced Computed Tomography of case 2 showing bilateral adnexal tubular cystic lesion of size 6.2 x 1.9 cm on the right and 6.4 x 2.5 cm on the left adnexa with free fluid in the pouch of Douglas.

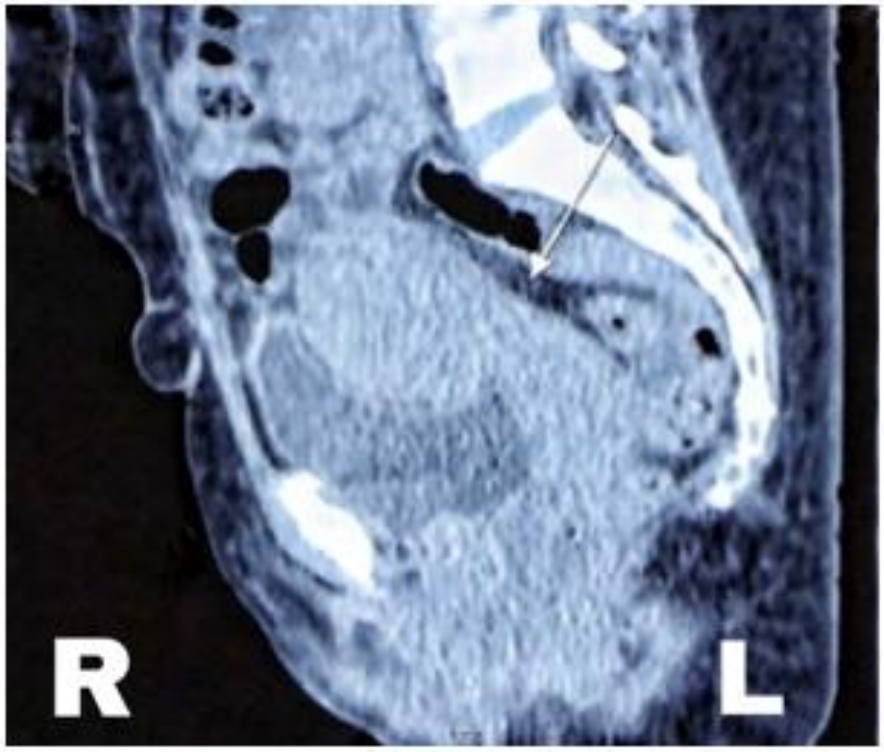

Figure 4: Sagittal section of abdomen and pelvis in Computed Tomography of case 2 showing tubular cystic lesion occupying the pouch of Douglas.

Case 3

A 26-year-old lady, married for 5 years with primary infertility was referred to our center for surgical management of endometriotic cyst. She gave a history of chronic pelvic pain and dyspareunia for which she was treated at various hospitals for 3 months. She had no significant past medical history. She was thin built. Her vitals were stable. Per abdominal examination revealed tenderness in the left iliac fossa and suprapubic region. Per vaginal examination revealed fullness in the left fornix. Pelvic ultrasound done 3 months back showed a large left adnexal cystic lesion of size 8.8 x 7.6 cm with peripheral partial thick septations, extending to the pouch of Douglas and adherent to the lateral wall of the uterus. There was no evidence of vascularity. Another homogenous cystic lesion of size 6.5 x 4.2cm was seen in the pouch of Douglas adherent to the posterior wall of the uterus. Both ovaries couldn't be visualized separately. MRI abdomen and pelvis showed a tubular cystic lesion in the right, probably a haematosalpinx of size 3 x 1.5 x 1.9cm and the right ovary was noted adjacent to the tubular lesion. Left tubo ovarian multiloculated cystic lesion of size 8.3 x 3.8 x 4cm was also noted probably an endometriotic cyst (Figure 5).

Her tumor markers (CA125) were within normal limits. Laboratory evaluation showed hemoglobin level of 7.5gm/dl and other investigations were normal. She was transfused with 2 units of packed cell before surgery. Her intraoperative findings revealed dense omental adhesions to the anterior abdominal wall extending to the perihepatic region (Fitz Hugh Curtis syndrome) and intrapelvic adhesions with left tubo ovarian mass of size 8 x 6cm adherent to the right tube.

The left ovary couldn't be visualized separately. The patient underwent adhesiolysis, abscess drainage, and peritoneal lavage with copious saline. An intraabdominal drain was placed. Pus was sent for culture and sensitivity. The total duration of surgery was 2 hours and about 75 minutes were spent on adhesiolysis.

Intraabdominal drain was removed on postoperative day 3. Her pus culture was sterile probably due to previous broad-spectrum antibiotic usage. The patient improved symptomatically and was discharged on postoperative day 4. She was continued on oral antibiotics for 14 days and was followed up for 2 months.



Figure 5: Sagittal section of abdomen and pelvis in Magnetic Resonance Imaging with contrast of case 3 showing cystic lesion of size 8.3 x 3.8 x 4 cm adherent to the posterior wall of the uterus.

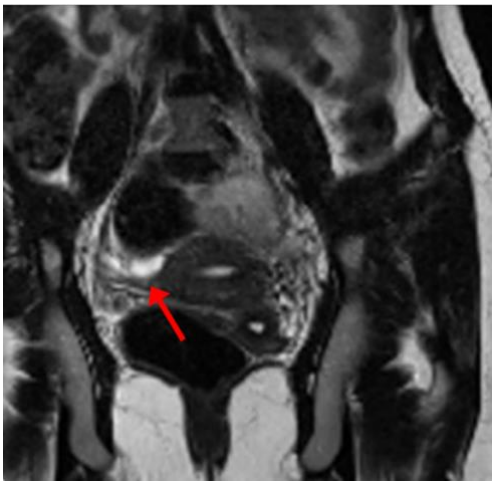

Figure 6: Coronal section of abdomen and pelvis in Magnetic Resonance Imaging with contrast of case 3 showing a tubular cystic lesion in the right of size 3 x 1.5 x 1.9 cm.

Clinical Video

*Clinical videos related to this article can be found online at:

Discussion

Initial management of a woman with a suspected tubo–ovarian abscess is dictated by clinical findings and radiological imaging [1]. The management of tubo-ovarian abscesses remains broad ranging from conservative management with antibiotics for smaller abscesses to minimally invasive procedures like abscess drainage under antibiotic coverage and surgical management for abscesses more than 5.5.cm in size [3,8,9,10]. The success rate of broad-spectrum antibiotic management ranges from 34% to 88%, with a high recurrence rate [3]. The failure rate of antibiotic therapy is higher in a patient with a large abscess due to limited penetration of antibiotics into the anaerobic natured abscess cavity [9,10].

Sequelae of conservative management can be dense adhesions, recurrent abscess, the persistence of disease, chronic pain and infertility [1,3,5]. It is not clear why there is a progression from pelvic inflammatory disease to a tubo-ovarian abscess; a delay in treatment of pelvic inflammatory disease is highly likely but the virulence of the causative pathogen might make a tubo-ovarian abscess more likely [2,11,12]. In case #1 the patient was treated with intravenous broad-spectrum antibiotics for 10 days at a local hospital before surgical intervention in our hospital. The patient had failed to respond to antibiotics, this could be related to limited penetration of antibiotics into the abscess cavity. Similarly, in case #3 patient was on multiple courses of antibiotic treatment for 3 months. Prolonged antibiotic usage could be the reason for organized pus in cases #1 and 3. In case# 2 patient had an early intervention within 24hrs due to sepsis and rapidly deteriorating clinical condition suspecting tubo-ovarian abscess rupture [1]. There was liquid pus with bilateral pyosalphinx with minimal intrapelvic flimsy adhesions though the abscess was more than 5cm. One of the serious complications of tubo-ovarian abscess is rupture of abscess leading to acute abdomen and sepsis. In the presence of sepsis, appropriate resuscitation and prompt surgery with concurrent commencement of broad-spectrum antibiotics should be considered [1]. Surgery should be performed promptly to avoid long exposure to pus, which may exaggerate or worsen adhesions and fibrosis due to inflammation [1]. In clinical practice, surgical treatment is necessary if the patient exhibits no clinical response to antibiotics, rapid clinical deterioration even after antibiotic therapy for 48-72 hours or ruptured abscess as suggested by Robert and Dockery et al [13]. Optimal timing for surgery is hence challenging [1].

Surgery for a tubo-ovarian abscess is clinically difficult due to fragile necrotic tissue leading to tissue collapse and hemorrhage and may lead to organ injury [1]. In case #1 patient had bilateral tubo-ovarian mass with dense intrapelvic adhesions due to the presence of inflammation and necrotic material involving most of the pelvis. The surrounding tissues, such as the colon, omentum, uterus, and anterior abdominal wall were entrapped in the organized abscess and the bladder was also stuck closely to the uterus anteriorly [3]. Surgery for tubo ovarian abscesses was quite difficult and prolonged because of fragile tissue, necrotic debris and sheets of pus [1]. The total duration of surgery was 240 minutes and about 120 minutes of it were spent on adhesiolysis. Similarly, in case #3, the patient underwent fertility-preserving surgery comprising of inspection of the peritoneal cavity, adhesiolysis, broad incision of abscess cavity, drainage of pus, irrigation of cavity with saline and cauterization of superficial endometriotic deposits and vesicles [8]. The total duration of surgery was 120 minutes and about 75 minutes were spent on adhesiolysis. The duration of surgery in case 2 was only 60 minutes and was quite easy when compared to cases #1 and 3 due to very minimal intrapelvic adhesions. Surgical intervention was tough in cases #1 and 3 and was attributable to dense adhesions because of chronic inflammation. From our case series, we infer that earlier the surgical intervention lesser the operative difficulty and faster the patient recovery.

Although there are antibiotic guidelines for antibiotic management by CDC, there are no uniform guidelines for surgical intervention [1]. However, the 2011 UK National Guideline for the management of Pelvic Inflammatory Disease state that laparoscopy may help with the early resolution of the disease by dividing adhesions and draining pelvic abscesses as seen in our case series [14]. There are various options for the approach to surgical intervention for tubo- ovarian abscess: laparoscopy or laparotomy with abscess drainage, unilateral or bilateral salpingectomy or salpingo-oophorectomy and pelvic clearance [1]. The key advantage of laparoscopy is that it is less invasive, with a smaller incision, less postoperative pain and faster recovery [1,3].

Laparoscopy helped in the simultaneous diagnosis and treatment of tubo-ovarian abscess in our case series as imaging modalities can give inconclusive results. Laparoscopy also helped us in detecting the involvement of other organs and associated complications in pelvic inflammatory disease like Fitz Hugh Curtis syndrome as noted in cases #2 and 3 [15]. The operative procedure in our patients involved blunt lysis with hydro dissection of adhesions, drainage of abscess, debridement, aspiration of purulent material from the pelvic cavity, removal of necrosis and irrigation of the peritoneal cavity as suggested by Buchweitz et al [8,16,17,18]. Bilateral salpingectomy was performed in cases 1 and 2 as they no longer desired future fertility and it helps to prevent recurrence as suggested by Buchweitz et al [1,8]. Peritoneal lavage was done with copious saline in all our cases with the patients in the Trendelenburg and the anti –Trendelenburg position in our case series [8]. The above-mentioned measures might have had a role in increased response to antibiotics and faster recovery in the postoperative period. Successful tubo-ovarian abscess drainage refers to a complete response to treatment, no secondary interventions, no conversion to laparotomy and a successful long-term outcome [19].

In our patients, the abscess size was more than 5cm and early surgical intervention and removal of infective foci led to rapid recovery. This was consistent with the studies that early laparoscopic surgical intervention for tubo ovarian abscess and pelvic abscess leads to shorter surgery times, minimal blood loss, shorter postoperative hospital stays and faster recovery as seen in case 2 [5]. A pelvic abscess diameter of more than 5.5cm was significantly associated with antibiotic failure and requires surgical intervention [3].

Postoperative antimicrobial treatment in all our cases consisted of intravenous administration of Piperacillin Tazobactam 4.5 g thrice daily, metronidazole 500mg thrice daily and Amikacin 750mg once a day for 7 days. This regimen was modulated according to the results of the microbiological examination and oral antibiotics were continued for 14 - 28 days [8].
In cases 1 and 3 pus was organized and pus culture and culture sensitivity showed no growth of any microorganism probably due to prior antibiotic usage.

Women aged around 45 years are more likely to have a larger abscess with higher inflammatory markers than younger women who paradoxically have more risk factors [20]. Women with co-existing endometriosis are more likely to have more severe pelvic inflammatory disease which was consistent with our third case. The incidence was 2.3% in women with co-existing and endometriomas compared with 0.2% in women without endometriomas [21].

All of our patients were anemic and of poor immunity which could be one of the reasons for the rapid progression of pelvic inflammatory disease to a tubo-ovarian abscess in addition to the virulence of the organism. Hence we infer that general health conditions and immunity play an important role in the progression of the disease.

Conclusion

Early laparoscopic surgical intervention in abscesses more than 5cm gives a favorable outcome to the patient irrespective of the initial response to antibiotics. Timely laparoscopic intervention in patients with failed medical therapy is beneficial to avoid prolonged hospitalization, and antibiotic usage and to assist in faster recovery. Diagnosis of a tubo-ovarian abscess requires a high degree of suspicion as delay in the diagnosis was the major reason for late surgical intervention more commonly in rural setups. Further studies are required to determine whether laparoscopic management of smaller tubo-ovarian abscesses achieves more favorable outcomes than conservative treatment with antibiotics alone.

Abbreviations

CDC - Center for Disease Control and Prevention.

CECT- Contrast Enhanced Computed Tomography.

CT - Computed Tomography.

MRI - Magnetic Resonance Imaging.

POD - Pouch of Douglas.

Acknowledgements

We thank our patients, hospital staff and our technicians who assisted in collecting data and editing videos.

Author's Contributions

Sivakumar Thangappan: Conception of the work, Design of the work, Revising the work critically for important intellectual content, Final approval of the version to be published, agree to be accountable for all aspects of the work in ensuring that questions related to the accuracy or integrity of any part of the work are appropriately investigated and resolved.

Dolly Johnrose: Conception of the work, Revising the work critically for important intellectual content, Final approval of the version to be published, agree to be accountable for all aspects of the work in ensuring that questions related to the accuracy or integrity of any part of the work are appropriately investigated and resolved.

Sharmila Sakthykumari Vandhana: Conception of the work, Acquisition of data, Analysis of data, Interpretation of data, Drafting the work, Revising the work critically for important intellectual content, Final approval of the version to be published, agree to be accountable for all aspects of the work in ensuring that questions related to the accuracy or integrity of any part of the work are appropriately investigated and resolved.

REFERENCES

1. Munro K, Gharaibeh A, Nagabushanam S, et al. Diagnosis and Management of Tubo-ovarian Abscesses. The Obstetrician & Gynaecologist. 2018; 20: 11-9.
2. Chappell CA, Wiesenfeld HC. Pathogenesis, Diagnosis, and Management of Severe Pelvic Inflammatory Disease and Tubo-ovarian Abscess. Clin Obstet Gynecol. 2012; 55: 893-903.
3. Jiang X, Shi M, Sui M, et al. Clinical Value of Early Laparoscopic Therapy in The Management of Tubo-ovarian or Pelvic Abscess. Exp Ther Med. 2019; 18: 1115-1122.
4. Kairys N, Roepke C. Tubo-ovarian Abscess. [Updated 2021 Jul 18]. In: Stat Pearls [Internet]. Treasure Island (FL): Stat Pearls Publishing. 2022.
5. Shigemi D, Matsui H, Fushimi K, et al. Laparoscopic Compared with Open Surgery for Severe Pelvic Inflammatory Disease and Tubo-ovarian Abscess. Obstet Gynecol. 2019; 133: 1224-1230.
6. Mirhashemi R, Schoell WM, Estape R, et al. Trends in The Management of Pelvic Abscesses. J Am Coll Surg. 1999; 188: 567-572.
7. Grace Ming Fen Chan, Yoke Fai Fong, Kai Lyn Ng, et al. "Tubo-Ovarian Abscesses: Epidemiology and Predictors for Failed Response to Medical Management in an Asian Population", Infectious Diseases in Obstetrics and Gynecology, 2019.
8. Buchweitz Olaf, Diedrich Klaus. Organ-Preserving or Ablative Treatment? Which Endoscopic Procedure is Sensible for Treating Tubo-Ovarian Abscesses? J Pelvic Surg. 2002; 8: 3–5.
9. Chu L, Ma H, Liang J, et al. Effectiveness and Adverse Events of Early Laparoscopic Therapy Versus Conservative Treatment for Tubo-ovarian or Pelvic Abscess: A Single-Center Retrospective Cohort Study. Gynecol Obstet Invest. 2019; 1-9.
10. Mizushima T, Yoshida H, Ohi Y, et al. Evaluating the Risk Factors for Developing Resistance to Parenteral Therapy for Tubo-ovarian Abscess: A Case-Control Study. J Obstet Gynaecol Res. 2013; 39: 1019-1023.
11. Dessein R, Giraudet G, Marceau L, et al. Identification of Sexually Transmitted Bacteria in Tubo-ovarian Abscesses Through Nucleic Acid Amplification. J ClinMicrobiol. 2015; 53: 357-409.
12. Sordia-Hernández LH, Serrano Castro LH, Sordia-Piñeyro MO, et al. Comparative Study of The Clinical Features of Patients with a Tubo-ovarian Abscess and Patients with Severe Pelvic Inflammatory Disease. Int J GynaecolObstet. 2016; 132: 17-19.
13. Roberts W, Dockery JL. Operative and Conservative Treatment of Tubo-ovarian Abscess Due to Pelvic Inflammatory Disease. South Med J. 1984; 77: 860-863.
14. Grazia Porpora M, Gomc V. The role of Laparoscopy in The of Pelvic Pare in Women of Reproductive Age. FertUSteril. 68: 765-779.
15. Basit H, Pop A, Malik A, et al. Fitz-Hugh-Curtis Syndrome. [Updated 2022 Mar 19]. In: Stat Pearls [Internet]. Treasure Island (FL): Stat Pearls Publishing 2022.
16. Johns DA. Laparoscopic Treatment of Tube-ovarian Abscess, in: Sutton C, Diarnand M reds) Endoscopic Surgery of Gynaecologists, Third Printing. W.B. Saunders, London. Philadelphia, Toronto, Sydney, Tokyo. 1994; 154-158.
17. Nezhat CR. Operative Gynecologic Laparoscopy: Principles and Technique. 1st ed. McGraw-Hill, New York, St Louis, S~mFrancisco, London, Milan, Sydney, Toronto, Tokyo. 1995; 185-201.

18. Clinical Effectiveness Group, British Association for Sexual Health and HIV. UK National Guideline for The Management of Pelvic Inflammatory Disease 2011.
19. Goje, Oluwatosin, Markwei, et al. Outcomes of Minimally Invasive Management of Tubo-ovarian Abscess: A Systematic Review. Journal of Minimally Invasive Gynecology 2020.
20. Halperin R, Levinson O, Yaron M, et al. Tubo-ovarian Abscess in Older Women: Is the Woman's Age a Risk Factor for Failed Response to Conservative Treatment? GynecolObstet Invest. 2003; 55: 211-215.
21. Kubota T, Ishi K, Takeuchi H. A Study of Tubo-ovarian and Ovarian Abscesses, with a Focus on Cases with Endometrioma. J ObstetGynaecol Res. 1997; 23: 421-426.